

A CASE STUDY:- RECURRENT UNILATERAL SIXTH CRANIAL NERVE PALSY AND ITS AYURVEDIC MANAGEMENT**¹*Dr. Umesh Verma and ²Dr. Ghanshyam Dilip Suryawanshi**¹Assistant Professor, Department of Shalakya – Tantra, Ayurved Jeevak Ayurvedic Medical College and Hospital Research Center.²Assistant Professor, Smt. K.C. Ajmera Medical College, Dhule Maharashtra.Article Received on
05 March 2025,Revised on 26 March 2025,
Accepted on 16 April 2025

DOI: 10.20959/wjpr20259-36398

***Corresponding Author****Dr. Umesh Verma**Assistant Professor,
Department of Shalakya -
Tantra, Ayurved Jeevak
Ayurvedic Medical College
and Hospital Research
Center.umeshverma61@gmail.com**ABSTRACT**

Sixth (Abducens) nerve palsy is the most common type and commonly occurs in raised intracranial tension. Due to Paralysis of lateral rectus muscles defective abduction of the eye ball, partially or completely. Most of the patients 6th nerve palsies experience diplopia headache and vomiting. For the relief of diplopia occlusion suitable prism correction various type of muscles transposition operations and Batulinum toxin injection use to treat antagonist muscles. According to Ayurveda Acharya Sushruta included under tritiya patalgata timir, sannipataja timir andalso Acharya Vabhata included under dwitiya patalgat timir. Case – A 33 Year young Female patients came to O.P.D. with complain of Headache diplopia and left eye ocular movement is restricted in the left side. Vata is predominant dosha and kapha is Anubnadh dosha hence – Nasaya with Anutaila Ekangveer Rasa Tribhuvan Kirti Ras Shirashool hara vajrani vati Brahmi Vati and Eye exercise were given to the patient for 6 month. The patient was assessed clinically for visual symptoms, MRI, was repeated before and after the treatment.

INTRODUCTION

The abducens nerve (CN-VI) is responsible for ipsi lateral eye abduction, Dysfunction of the abducens nerve can occur at any point of its transit from the pons to the lateral rectus muscle resulting in sixth nerve palsy.

In adults, the risk factors for abducens nerve palsy can be categorized as vasculopathic or non-

vasculopathic. Vasculopathic risk factors are more common in older patients and may include conditions such as diabetes. On the other hand non-vasculopathic causes can be present in adults, children and may involve various risk factors such as trauma, inflammation, or compression.

In Ayurveda its included drstigata Roga – Timir, Acharaya Sushruta explain Tritya patalgata timir and Acharya Vagbhata explain dwitiya patalgata timir.

Here the location of dosha in dristi leads to altered visual perception as

Location of Dosha in Dristi	Effect
1. Lower part	- Loss of near vision
2. Upper part	- Loss of distance vision
3. Sides	- Loss of peripheral vision
4. All around	- Object appear overlapped
5. Centre (ॐ-μ-ॐ-ॐ-ॐ)	- Double vision
6. Two places (x«-ॐ-ॐ-ॐ-ॐ)	- Images appears as they are three in no.
7. Unstable (ॐ-ॐ-ॐ)	- Several images of one object

In Laterla rectus palsy abducens nerve is involved so vata dosha predominant and kapha is anubandhi dosha hence Vatashamak, Brimhana Jeevaniya, Rasayana, Kaphashamak, Amapachan Chikitsa with nasaya and eye exercise is indicated.

AIMIS AND OBJECTIVE

- To Explore pathogenesis of sixth nerve palsy
- To evaluate the effect of drugs indicated for sixth nerve palsy

MATERIAL AND METHOS

Case history – A 33 year young female patient came to outpatient department for Headache, double vision, diminished of vision, vomiting and restricted left eye movement away from nose since 3 month.

No history of diabetes mellitus, hypertension and other systemic diseases. The corrected vision with glass 6/6 and N6 both eye.

The previous MRI- Shows few small T2 / Fair hyper intensity - involving bilateral periventricular sub cortical white matter – region Ischemic / Non-specific.

Previous treatment – Patient had same sign and symptoms since 2 year back in some eye (Left Eye) for that the ophthalmologist given Oral steroid Methylprednisolon in taper dose

with Lubricant eye drop and Antioxidant.

She recover after 3 month but after 6-7 month she again got same symptoms and she tooked again oral steroid methylprednesolon and Review with Neurphysician – he added Antianxiety teb-migrabeta, Antibacterial – Eropam, Antiepileptic tablet Diever (250 mg) with Antigastritis tablets pantaprazole + Domperidom.

She Again relived from symptoms after two month but again she developed same complain with diminished of vision when the all medications going on.

Patient then approached for ayurvedic line of management.

Examination

Left eye	Right eye
Visual Activity with Glass – 6/9 & N6	6/6 & N6
Visual Activity without Glass – 6/36 & N6	6/36 & N6
Cornea & Anterior Segment – Normal	Normal Pupil – both
eye round regular reacting to light, No RAPD Colour vision both eye – Normal	
Funduscopy both eye – Normal, CDR 0.3 : 1	
NRR – Healthy	

Pathogenesis

Hetuseven – Vata Aahar and vihar Purvarup – Headache & Vomiting

Rup – Double vision, DOV, restricted eye movement.

Dusha Dushya - vata and kapha

Sthan – Left eye

Chikistsa sutra – Vata Kapha Shamak, Bhrimhana, Jeevaniya, Rasayana Amapachana and eye exercise up – down, left – right, oblique movement 10-12 times per day.

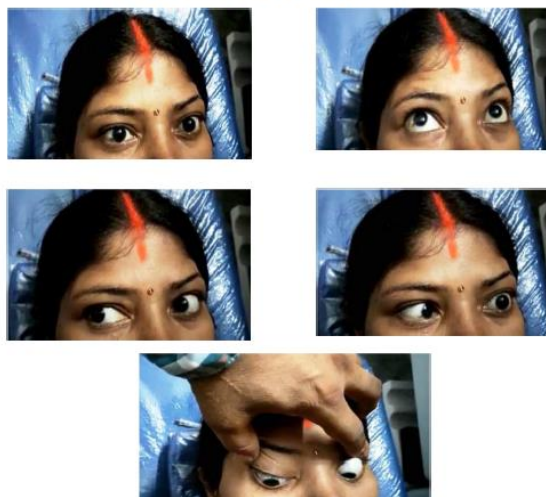1. Tab Ekangveer Ras 125 mg 1 Tab TDS
2. Tab Bramhi Vati 125 mg 1 Tab TDS
3. Tab Shirshool hara 500 mg 1 Tab TDS
4. Tab Tribhuvan Kirti Ras 125 mg 1Tab TDS
5. Nasaya with Anutaila 2 drop each nostril (Patimarsh)
6. Eye Exercise

Medicines were given to the patient for 6 month and fallow up taken every 30 days.

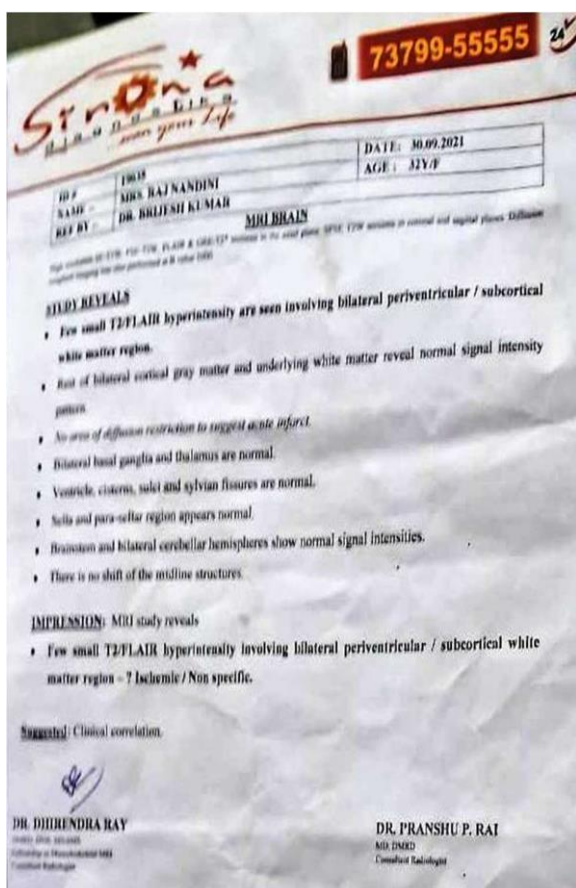
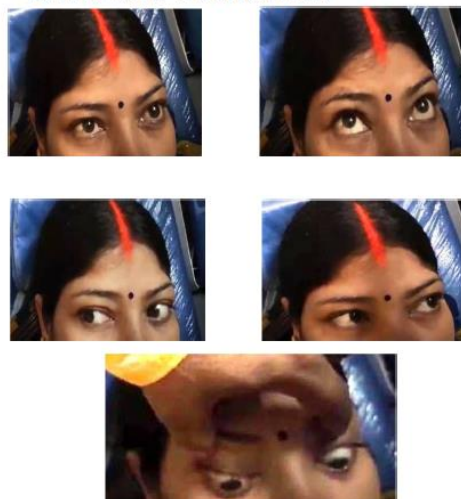OBSERVATION AND RESULT

There was remarkable improvement in patient sing and symptoms. Patient got total relief on headache, Diplopia, Vomiting and non moving of left eye away from nose is cured completely which shown in the picture of before and after the treatment, also MRI report.

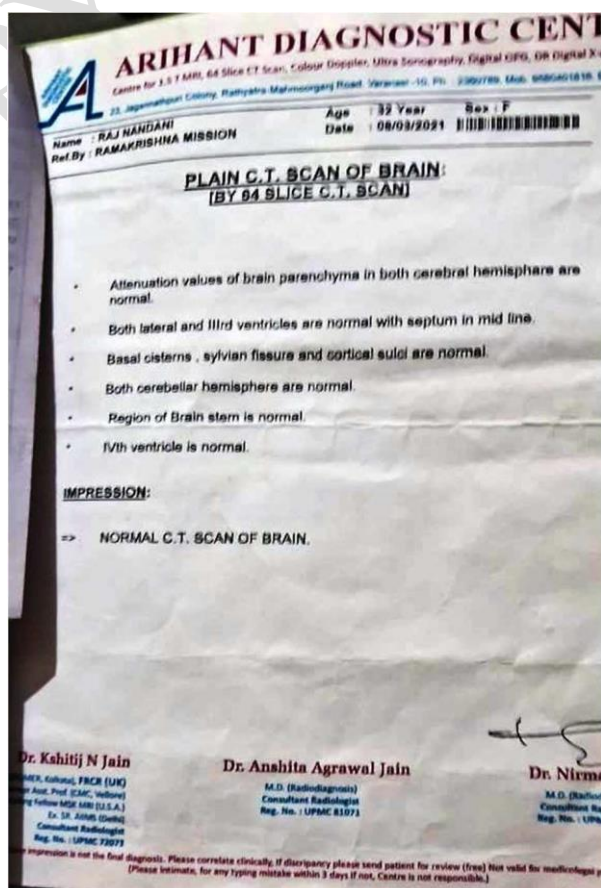
Before the Treatment



After the Treatment



MRI & C.T.Scan Before the Treatment



MRI After the Treatment

Table 1: Metod & Material.

Sr.No.	Visual Activity	Right Eye	Left Eye
1	Distance vision without glass	6/36	6/36
2	Distance vision with glass	6/6	6/9
3	Near vision	N6	N6
4	Colour vision	Normal	Normal
5	Pupil	No RAPD	No RAPD
6	IOP	14.6 mm Hg	15.3 mm Hg
7	Extra ocular muscles movement	Normal	Difficulty to abduct left eye (can not move away from nose)
8	Funduscopy	Normal	Normal

DISCUSSION

This most common type palsy commonly occurs in raised intra- cranial tension. According to Ayurveda its tritiya patalgata disease.

The patient sign – symptoms and clinical examination reveled prominence of vitiated vata and kapha dosha hence treatment was planned by focusing on these doshas.

- 1) Ekangveer Ras - Vatashamak, Brimhana, Jeevaniya, Rasayana and Vishagna guna specially used for vataja diseases.
- 2) Tab Bramhi Vati – It indicated in vata – kapha pradhan conditions and also strengthen the Brain cells.
- 3) Tab Shriashoolhara Vajrani Vati – Vata Shamak cure Ama- kapha condition, increase blood in body.
- 4) Tribhumvan Kirti Ras – Vata – Khapahara, Unexplained Headache, heavyness on head.
- 5) Nasaya with Anutaila – helped in alleviating vata dosha restores, the normal functional ability of affected nerves and improve blood circulation.
- 6) Eye exercise – Upword – Downword, Left – Right, oblique movement of eye 10 to 12 times per day.

CONCLUSION

The lateral rectus palsy compaired with Tritiya patal gata (According to Sushrut) & Ditiya patalgata timir (According to Vaghbhat) lead to Headache, diplopia, Vomiting, restricted eye movement which affect the patient daily activities.

Patient got symptomatic relief without reoccurrence (since One & half year). Patient also become independent of topical and oral steroids.

The bird eye view of Ayurveda concluded that we should not cure the disease but also prevent reoccurrence of same disease to same patient.

REFERENCE

1. Susruta Samhita – Kaviraj Ambikadatta Shashtri, Part II, Uttaratanttra – Edition 2015 Chaukhambha Sanskrit Sansthan Varanasi, 104,105.
2. Taxt book of Shalakyatantra, Chawkhamba Vishwabharati Series, Varanasi, Vol.I Netra Roga.
3. Rastrantrasar & Siddha Prayog Sangrah Part I, Swami Krishnanad, Krishna Gopal Ayurved Bhawan (Ajmer) Rajasthan, Jan. 2010.
4. Astangasangrah, Ravi Dutta Tripathi reprint 2005, Chaukhambha Sanskrit Sansthan Varanasi.
5. Ashtanga Hridaya Uttarsthan, Kaviraja Atridev Gupta Chaukhambha Sanskrit Sansthan Varanasi Edition Reprint, 2011.
6. Charaka Samhita, Pt.Kashinath Shastri and Gorakhnath Chaturvedi reprint 2008 Varanasi Chaukhamba Bharti Academy, Sutra Sthana chap 14/2024.
7. Comprehensive Ophthalmology – A.K. Khurana 5th edition 2014 Published by New Age International (P) Ltd., 350.
8. The wills eye manual – Zia Chaudhuri, 1st South Asian edition, Published by wolters Kluwer – New delhi, 47.
9. Parson's Diseases of eye - Ramanjit sihota.